



Rett syndrome associated with continuous spikes and waves during sleep

Mouna AL HUSNI AL KEILANI¹, Sophie CARLIER¹, José GROSWASSER², Bernard DAN¹ and Nicolas DECONINCK¹

¹Department of Neurology - Hôpital Universitaire des Enfants Reine Fabiola, Université Libre de Bruxelles (ULB), Brussels, Belgium;

²Sleep Unit - Hôpital Universitaire des Enfants Reine Fabiola, Université Libre de Bruxelles (ULB), Brussels, Belgium

Abstract

Major speech impairment is a cardinal feature of Rett syndrome. Epilepsy, of variable presentation, is also frequently described. We report a girl who presented rapid speech regression while EEG showed continuous spikes and waves during slow sleep. The clinical picture was consistent with Rett syndrome, confirmed by MECP2 mutation R133C. We hypothesized that speech regression was partially related to nocturnal epileptic activity. Several antiepileptic drugs were used unsuccessfully but valproic acid was accompanied by improvement of verbal fluency, social interaction and manual abilities as measured by the Quebec Scale of Adaptive Behaviors and the Rett syndrome adapted Kerr scale. Continuous spikes and waves during slow sleep are unexpected in the early stages of Rett syndrome. This report suggests that it might contribute to the clinical impairment, in particular communicative capabilities, and that adequate antiepileptic treatment may be beneficial.

Key words: Rett syndrome; MECP2; Continuous spikes and waves during sleep; Speech delay.

Introduction

Rett syndrome is a neurodevelopmental disorder affecting girls almost exclusively, characterized by early neurological regression with severe motor, cognitive and communication impairment. Diagnosis is primarily based on clinical criteria including deceleration of head growth from the first years of life, regression with hand stereotypies, reduced manual and communication skills, scoliosis, abnormal gait and sleep disturbances (1, 2). Rett syndrome is caused by *MECP2* mutations (3, 4), with some genotype-phenotype correlations (5, 6). Epilepsy, which is a frequent clinical problem, may have an atypical presentation, posing differential diagnosis difficulties (7). It is most common in stages II and III of the disease, but is rarely problematic beyond 10 years of age.

Seizures may display large variations in their typology: tonic, generalized tonic-clonic, complex partial, myoclonic, atonic, etc. (8). The electroencephalogram is almost invariably abnormal, showing loss of expected developmental features, rhythmic slow (theta) patterns primarily in the frontal central regions and diffuse or generalized spikes or spikes and waves (9). We describe a girl whose speech regression was contemporaneous with continuous spikes and waves during sleep, actually signalling the diagnosis of Rett syndrome.

Case report

A 3½ year-old girl presented with language regression from the age of three. Previous medical and family history was unremarkable with a normal birth weight and head circumference. Until 2½ years, milestones were achieved in the normal range, including communication skills. She then developed manual beat/friction stereotypies with progressive loss of manual function. From around 3 years, she lost previously reported openness toward social interaction. She had reduced eye contact and joint attention, seemed inattentive and did not respond to her name or to complex orders. Speech was limited to a few single words, and word repetition was not observed. She did not perform symbolic activities such as gesture imitation, setting in scene or drawing. She never presented any clinical seizures.

On clinical examination, head circumference was at the 25th percentile. Nonverbal communication was extremely poor with an inconstant visual contact. She showed hypermotor behavior, prominent stereotyped movements of both hands, severe bimanual dyspraxia and walking with marked lateral swinging. Her development was evaluated using the Quebec Scale of Adaptive Behaviours, Rett syndrome adapted Kerr scale and N-EEL scale for language (11, 12) (Table 1).

Table 1
Psycho-developmental evaluation

| <i>Evaluation 4 years, 4 months (before steroids)</i> | <i>Evaluation 5 years 2 months (after 8 months valproic acid introduction)</i> |
|--|---|
| Adapted Kerr scale (Leonard 2003 <i>et al.</i>). Items for which some changes were observed over time | |
| <i>Feeding</i> - No attempt <i>Speech</i> - Very few single words <i>Gross motor function</i> - Walks normally; difficulties descending stairs <i>Hand use</i> - Acquired and lost <i>Frequency of hand stereotypies</i> - Dominating to constantly <i>Voluntary hand use</i> - None | <i>Feeding</i> - Using fingers to feed ; unable to use a spoon to eat <i>Speech</i> - More than single words <i>Gross motor function</i> - Slight improvement of balance; descending stairs <i>Hand use</i> - Improved <i>Frequency of hand stereotypies</i> - No change <i>Voluntary hand use</i> - Some hand use, feeding with help, more frequent and better objects prehension |
| Quebec Scale of Adaptive Behaviors (EQCA) | |
| <i>Feeding</i> - Cannot eat alone and difficulties for drinking <i>Hygiene, toilet using and dressing/undressing</i> - Dependent to wash herself- - No sphincter control- Need help, cannot dress herself alone <i>Fine motor skills</i> - Prehension is basic - Can open the door but cannot close it - Independent to climb stairs but need help to go down <i>Global motricity</i> Abilities relatively well conserved <i>Receptive and expressive communication</i> - Absence of pointing - Language very poor and limited to a few words - Does not answer systematically to her name <i>Socialization</i> - Possible but poor visual eye interaction - Interaction when the patient is stimulated. No spontaneous interaction - Smile - No imitation <i>Games :</i> Absence of symbolic games | <i>Feeding</i> - Can use fingers to eat. Is unable to use a spoon to eat - Better to drink with a glass <i>Hygiene, toilet using and dressing/undressing</i> No change <i>Fine motor skills</i> No change <i>Global motricity</i> Slight improvement of balance <i>Receptive and expressive communication</i> - Absence of pointing - Improvement of verbal fluency and comprehension <i>Socialization</i> - Improvement of interaction mainly spontaneous approach - Smile - Imitation very limited <i>Games:</i> No change |

Biological work-up showed normal standard parameters. Brain MRI and auditory evoked potentials were normal. Heterozygous mutation R133C (g.66248 C > T) within the *MECP2* confirmed the diagnosis of Rett syndrome.

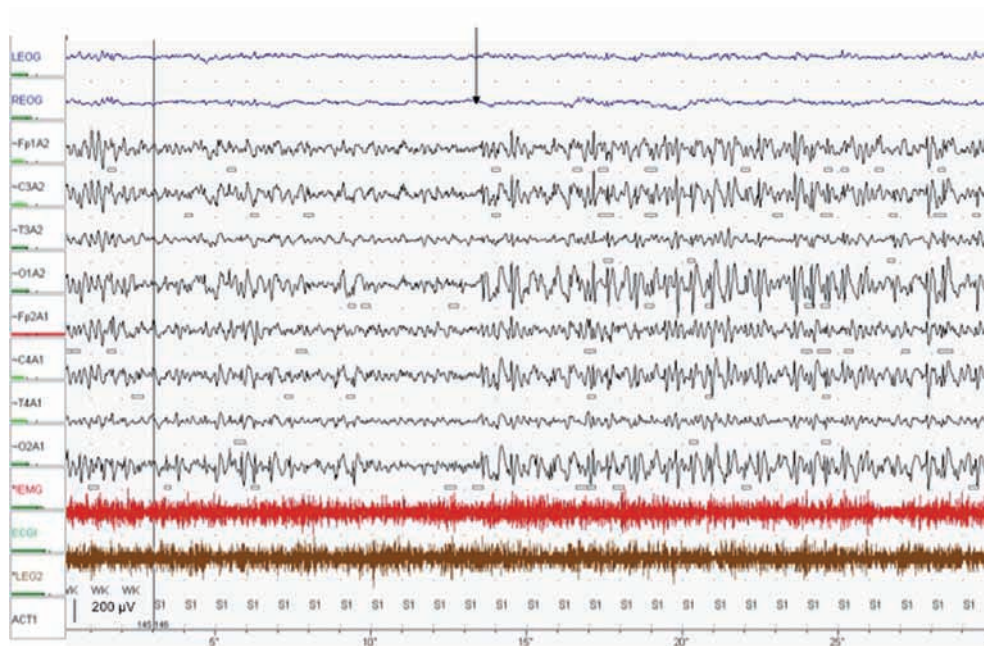
Standard EEG showed occasional left centro-temporal discharges without any clinical correlation. 24-hour EEG showed continuous spike-and-waves during slow-wave sleep (CSWS) with a spike-wave index of 75% (Fig. 1).

Clobazam (5 mg bid) and ethosuximide (25 mg/kg/day; from age 3 years 8 months to 3 years 10 months), topiramate (4 mg/kg/day; from age 3 years 10 months to 4 years), leviteracetam (50 mg/kg/day; from age 4 years to 4 years

4 months) and prednisolone (2 mg /kg/d; 2 months; from age 4 years 4 months to 4 years 6 months) were not accompanied by clinical or EEG improvement. Valproic acid given from the age of 4 years 6 months on was associated with a moderate but significant improvement of verbal fluency (mostly in repetition but also in denomination and lexical comprehension), social interaction, manual prehension abilities (see Table 1) and a reduction of 37% in the spike-wave index after 8 months of treatment.

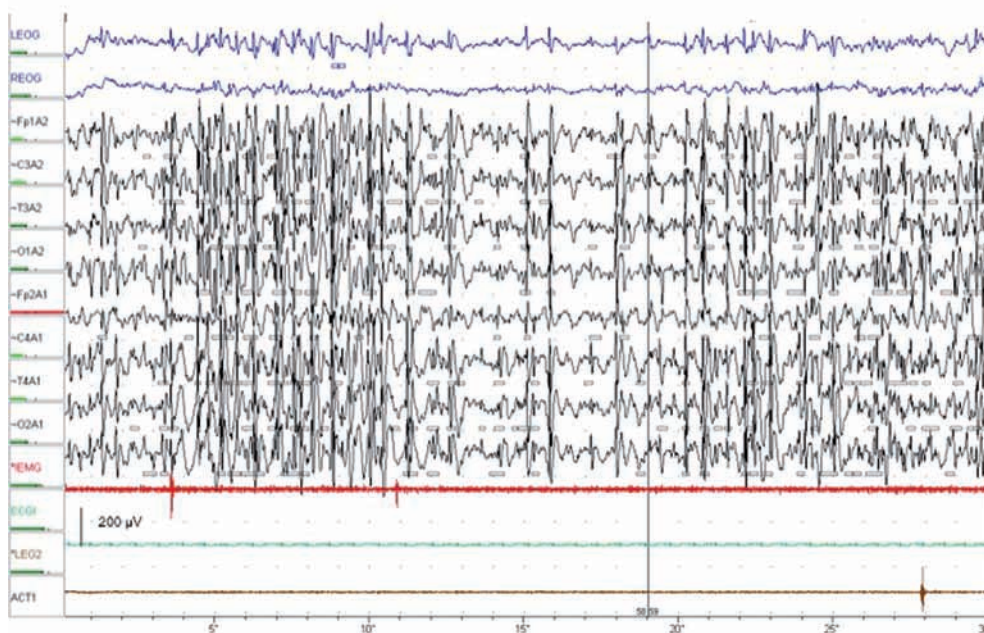
Discussion

This girl with Rett syndrome presented with electrical status epilepticus during slow-wave sleep



RETT SYNDROME & CSWS
TRANSITION FROM WAKE TO NONREM SLEEP

1 A



RETT SYNDROME & CSWS
NONREM SLEEP

1 B

FIG. 1. — Initial 24 hour EEG (3, 5 year-old). A) transition from wake to non REM sleep (see arrow); B) Non REM sleep; recording of CSWS with a spike-wave index of 75%. This index is defined as the total number of minutes of spikes and slow-wave abnormalities multiplied by 100 and divided by the total number of NREM sleep minutes. 30 seconds recording; vertical bar = 200 μ V on EEG recording.

coinciding with speech and behavioral regression. This electrographic phenomenon has been well documented in continuous spikes and waves during slow sleep (CSWS) and Landau-Kleffner syndrome (LKS), where it contributes to progressive neurological dysfunction and behavioral alterations (13, 14, 15). CSWS typically starts in 4-8 year-old children (14, 15, 16), two thirds of whom have normal previous neurocognitive development (17). CSWS was also reported in children with various early brain lesions (13, 15, 18). EEG often shows focal spike-waves during wakefulness. During NREM sleep, spike-waves spread and become continuous, occupying 50-85% or more of the time of sleep (19). In LKS, CSWS is associated with acquired aphasia, usually developing over a few months and affecting both receptive and expressive speech. Antiepileptic medication commonly improves communication skills in children with LKS (13, 15, 18).

Our patient presented at 3 years with speech and general communication skills regression. CSWS was identified but the clinical picture was evocative of Rett syndrome in stage II of the disease, confirmed by the demonstration of a R133C mutation in the *MECP2* gene. In stage II of the disease, sleep EEG shows frequent focal (central) or multifocal epileptiform abnormalities (9). In stage III, multifocal discharges and generalized slow spike waves patterns during NREM sleep are observed, often reaching the criteria for CSWS in stage IV (9, 10). To our knowledge, this has not been described previously at the early regression stage II, when the clinical diagnosis of Rett syndrome is commonly made.

Although CSWS and its implications on cognition have been poorly described in Rett syndrome, we find it reasonable to question its possible contribution to deteriorating some symptoms observed in our patient, such as speech and communication regression.

Patients harbouring the R133C mutation tend to show a milder phenotype, with better ambulation and hand use, and greater likelihood of using speech (12). Indeed, our patient showed normal development of motor and communications skills until the age of 2½.

In terms of treatment, only valproic acid induced improvement in verbal fluency, social interaction, manual stereotypies and spike-wave index. The observation period was however too short to consider long-term effectiveness of antiepileptic medications on the CSWS and its clinical repercussion.

Acknowledgement

We thank Pascal Cochaux, Genetic laboratory, Erasme, ULB for Rett molecular analyses.

REFERENCES

- Hagberg B. Clinical Manifestations and Stages of Rett Syndrome. *Ment Retard Dev Disabil Res Rev.* 2002;8:61-65.
- Jellinger KA. Rett Syndrome – an update. *J Neural Transm.* 2003;110: 681-701.
- Amir RE, Van den Veyver IB, Wan M, Tran CQ, Francke U, Zoghbi HY. Rett syndrome is caused by mutation in X-linked *MECP2*, encoding methyl-CpG-binding protein 2. *Nat Gen.* 1999; 23: 185-8.
- Gabellini D, Green MR, Tupler R. When enough is enough: genetic diseases associated with transcriptional derepression. *Curr Opin Genet Dev.* 2004; 14(3):301-7.
- Bebbington A, Anderson A, Ravine D, Fyfe S, Pineda M. *et al.* Kaufmann, H Leonard. Investigating genotype-phenotype relationships in Rett syndrome using an international data set. *Neurology.* 2008; 70(11):868-75.
- Neul JL, Fang P, Barrish J, Lane J, Caeg EB. *et al.* Specific mutations in methyl-CpG-binding protein 2 confer different severity in Rett syndrome. *Neurology.* 2008;70(16):1313-21.
- d'Orsi G, Demaio V, Minervini MG. Myoclonic status misdiagnosed as movement disorders in Rett syndrome: a video-polygraphic study. *Epilepsy Behav.* 2009;15(2):260-2.
- Pardal Fernandez JM, Jerez-Garcia P, Onsurbe-Ramirez I, Marco-Giner J. Rett syndrome: a case presenting with atypical seizures. *Neurophysiological and clinical aspects.* *Clin Neurophysiol.* 2004;34(1): 49-57.
- Glaze DG. Neurophysiology of Rett Syndrome. *Ment Retard Dev Disabil Res Rev.* 2002;8:66-71.
- Aldrich MS, Garofalo EA, Drury I. Epileptiform abnormalities during sleep in Rett syndrome. *Electroencephalogr Clin Neurophysiol.* 1990;75(5): 365-70.
- Maurice P., Morin D., Tassé MJ. Le développement de l'échelle québécoise des comportements adaptatifs: aujourd'hui et demain. *Revue francophone de la déficience intellectuelle.* 1992;3:147-151.
- Leonard H, Colvin L, Christodoulou J, Schiavello T, Williamson S. *et al.* Patients with the R133C mutation: is their phenotype different from patients with Rett syndrome with other mutations? *J Med Genet.* 200;40(5):pp e52.
- Tassinari CA, Rubboli G, Volpi L, Meletti G, d'Orsi G. *et al.* Encephalopathy with Electrical Status epilepticus during slow sleep or ESES syndrome including the acquired aphasia. *Clinical Neurophysiology* 2000;111(2):94-102
- Tassinari CA, Cantalupo G, Rios-Pohl L, Della Giustuna E and Rubboli G. Encephalopathy with status epilepticus during slow sleep: "The Penelope syndrome". *Epilepsia* 2009;50 (suppl 7):4-8.
- Nickels K, Wirrell E. Electrical status epilepticus in sleep. *Semin Pediatr Neurol* 2008;15(2):50-60.

16. Seth RD. Electroencephalogram in développemental delay: Specific electroclinical syndromes. *Sem Pediatr Neurol* 1998;5:45-51.
17. Bureau M. (1995). "Continuous spikes and waves during slow sleep" (CSWSS) : definition of the syndrome. In: Beaumanoir MBA, Deonna T, Mira L, Tassinari CA, ed., *Continuous Spikes and Waves during Slow Sleep* (pp 17-26). London : John Libbey 2002: 17-26.
18. Van Bogaert P, De Borchgrave V, De Cocq C, Deprez M, De Tiège X. *et al.* The epileptic syndromes with continuous spikes and waves during slow sleep: definition and management guidelines. *Acta Neurol Belg.* 2006;106:52-60.
19. Scheltens-de-Boer M. Guidelines for EEG in encephalopathy related to ESES/CSWS in children. *Epilepsia.* 2009;50 (Suppl. 7):13-17.

Dr. N. Deconinck, M.D., Ph.D.,
Department of Neurology,

Hôpital Universitaire des Enfants Reine Fabiola,
Université Libre de Bruxelles (ULB),
15 Avenue J.J. Crocq 15,
1020 Brussels (Belgium).
E-mail: nicolas.deconinck@huderf.be